

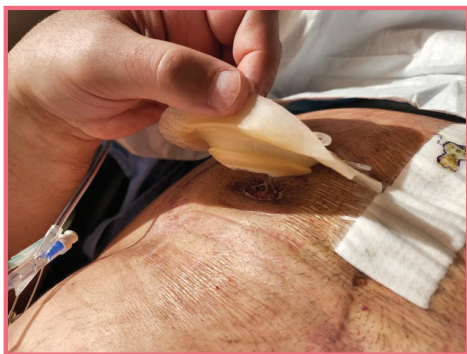Solution for a flush permanent end colostomy using deep convexity

eakin
freeseal[®]

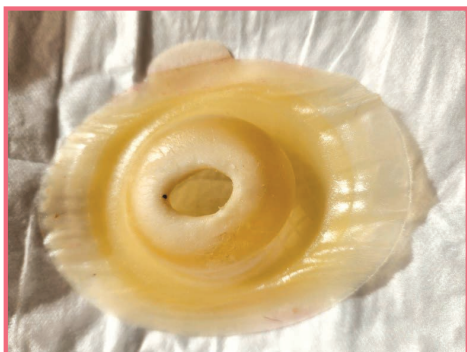Patient Profile

Gender: Male Age: 54 Reason for stoma surgery: Colorectal cancer

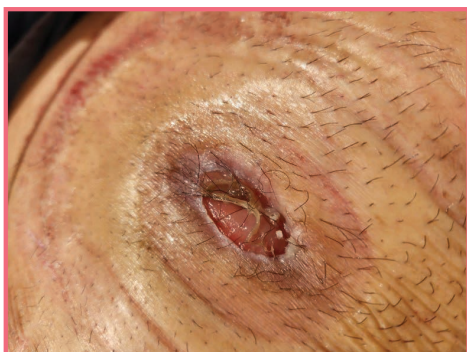
- Discharged home independent with stoma care Flush End colostomy
- Intact and flat peristomal skin
- Fitted with deep convexity two piece appliance



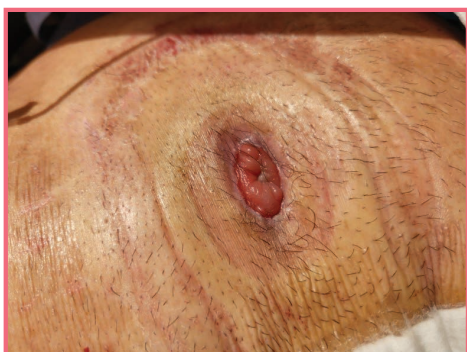1. Day 7 post abdominal perineal resection (APR). Currently nil gut function, but passing gas. Patient is using a two-piece deep convexity product as the end colostomy is small, flush and oval (14 x 25mm).



2. The product was easily removed from the skin, completely intact.
The seal remained completely adhered to the baseplate. The white area of the **eakin freeseal**[®] suggests that sweat and other fluids have been drawn into the product (wicking effect) keeping the skin free from maceration (waterlogging).



3. The peristomal skin is free of any gum residue. There is some gut-produced mucus only showing prior to cleaning.



4. After gentle cleaning it is evident that the **eakin freeseal**[®] is easy to remove, and remained completely intact, without any skin residue or maceration.

Case Study by Diana Hayes
Clinical Nurse Consultant / Stomal Therapy